

# Nailfold capillaroscopy in Buerger's disease: A useful tool?

Giacomo Maria Guidelli, Marco Bardelli, Antonella Fioravanti, Enrico Selvi

## Abstract

Thromboangiitis obliterans (TAO, or Buerger's disease) is a rare inflammatory vasculitis that commonly involves small and medium-sized arteries of the extremities of tobacco smokers between the ages of 25 and 50 years. Although the diagnosis is based on the clinical picture and angiographic findings, we studied the microvascular involvement by nailfold capillaroscopy. We evaluated by nailfold capillaroscopy 2 patients with Buerger's disease, at baseline and after 6 months of tobacco discontinuation and therapy with prostanoids. Both patients presented similar capillaroscopic abnormalities, resembling a scleroderma-like pattern. The microvascular rearrangement was significantly reduced after 6 months of evaluation. The capillaroscopic abnormalities shown in the two patients could be related to thromboangiitis obliterans, and nailfold capillaroscopy could be a useful tool to evaluate disease progression and the response to treatment.

**Key words:** Thromboangiitis obliterans, nailfold capillaroscopy, acral skin ulcers

## Introduction

Thromboangiitis obliterans (TAO, or Buerger's disease) is a relatively rare segmental non-atherosclerotic inflammatory disorder of peripheral blood vessels, affecting small and medium-sized arteries and veins of the extremities. Exposure to tobacco is central to the initiation, maintenance, and progression of the disease (1).

Although commonly accepted diagnostic criteria are still unavailable, nowadays, the most used are Shionoya's criteria (1-3). Discontinuation of tobacco is the cornerstone of therapy. Other forms of treatment, including vasodilators (prostaglandin analogs and calcium channel blockers), have all been tried, with limited effect in decreasing pain and avoiding amputation (1-3).

Patients may present with early findings of pain or coldness in the fingers and Raynaud phenomenon (RP), followed by rest pain and acral skin ulcers (3).

Nailfold capillaroscopy (NFC) is a simple and non-invasive technique that allows the *in vivo* assessment of the microvascular environment, and it has been demonstrated to be helpful in the differential diagnosis of some diseases, primarily capable of differentiating between primary and secondary RP, systemic sclerosis (SSc), and dermatomyositis (4-6).

Since TAO is a vasculitic syndrome characterized by small and medium vessel involvement, often associated with acral ulcers, the aim of our preliminary study was to investigate whether NFC could represent a tool in the diagnosis and follow-up of the disease during the acute phase and over a 6-month follow-up.

## Case Presentation

We evaluated two male patients who were referred to our outpatient clinic for RP and painful acral ulcers. The first patient, a 48-year-old man, presented with a 5-week history of pain in his hands and feet, ulcerations, and digital gangrene, which was associated with blue discoloration and claudication of both feet.

He was a lifelong heavy smoker (about 20 cigarettes/day since 20 years) but had no other cardiovascular risk factors. He had a history of RP affecting both hands for 2 years. The second patient, a 44-year-old man with a smoking history (about 25 cigarettes/day since 15 years), was referred for an ulcer of his second and third right fingers with a discharge of pus from the tip, which appeared 4 weeks before (Figure 1).

He also complained of instep foot claudication, which had progressed to ischemic rest pain bilaterally in both feet. He also had a 3-year history of superficial migratory thrombophlebitis and RP.



Division of Rheumatology, Siena  
University Surgery and Neurosciences  
Faculty of Medicine, Italy

Address for Correspondence:  
Giacomo Maria Guidelli, Division  
of Rheumatology, Surgery and  
Neurosciences Faculty of Medicine,  
Siena, Italy

E-mail: giacoguidelli@hotmail.com

Submitted: 01.04.2014

Accepted: 20.04.2014

Copyright 2014 © Medical Research and  
Education Association

Blood chemistry, including acute phase reactants, anti-neutrophil cytoplasmic antibodies, and anti-phospholipid antibodies, proved negative.

On angiographic assessment, both patients had normal proximal vessels but distal diseased vessels interspersed with normal blood vessels segments bilaterally, with multiple vascular occlusions, skip, and segmental lesions.

According to Shionoya's criteria, both patients were diagnosed as having TAO and, other than discontinuation of cigarette smoking, the patients were treated with intravenous Endoprost® (Iloprost, produced by Italfarmaco Spa), at a dosage of 1 ng/kg/min for 3 consecutive days and monthly and nifedipine.

Clinically, the patients presented with a significant reduction of rest pain and decrease of skin ulcers after the second monthly course of Endoprost® infusion (Figure 1).

Before the first administration and after 6 months of therapy, the patients underwent NFC evaluation. We examined the nailfold capillaries of fingers 2-5 bilaterally and considered the following parameters: the visibility of microcirculation (good/lower), the presence of enlarged loops and *microhemorrhages*, the visibility of the subpapillar venous plexus (SVP) (7), and the shape and length of capillary loops.

In both patients, the capillaroscopic findings at the basal time showed the presence of micro-

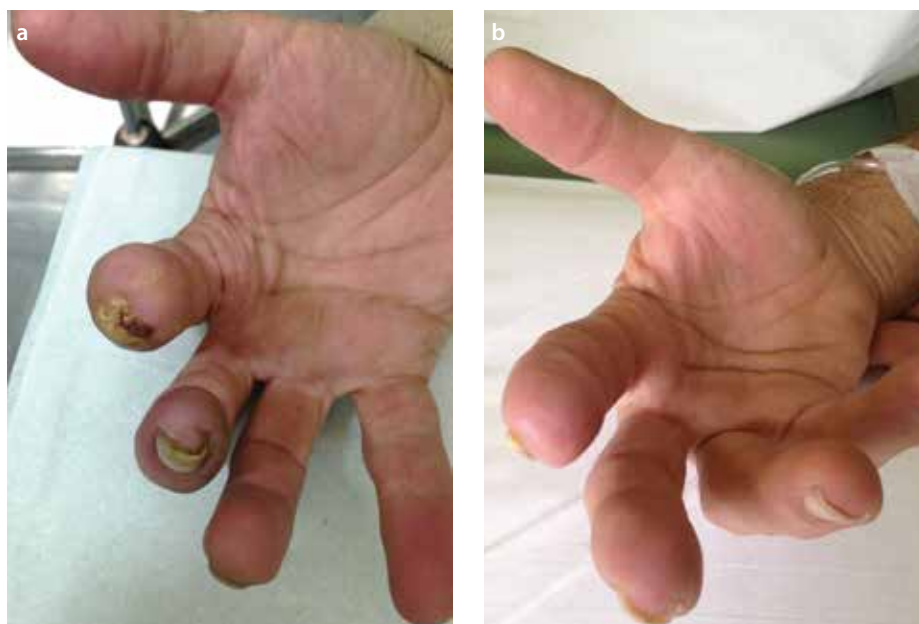hemorrhages, tortuosity, edema, derangement of capillaries, arrest of capillary blood flow, and isolated mega-capillaries (Figure 2). In addition, a "foggy aspect" due to local plasma extravasation from the damaged vessels was diffusely visible.

These findings were significantly reduced after 6 months, according to the clinical improvement. The nailfold vascular bed showed good visibility, with an increase in the number and density of capillaries, whose appearance did not reveal substantial structural abnormalities,

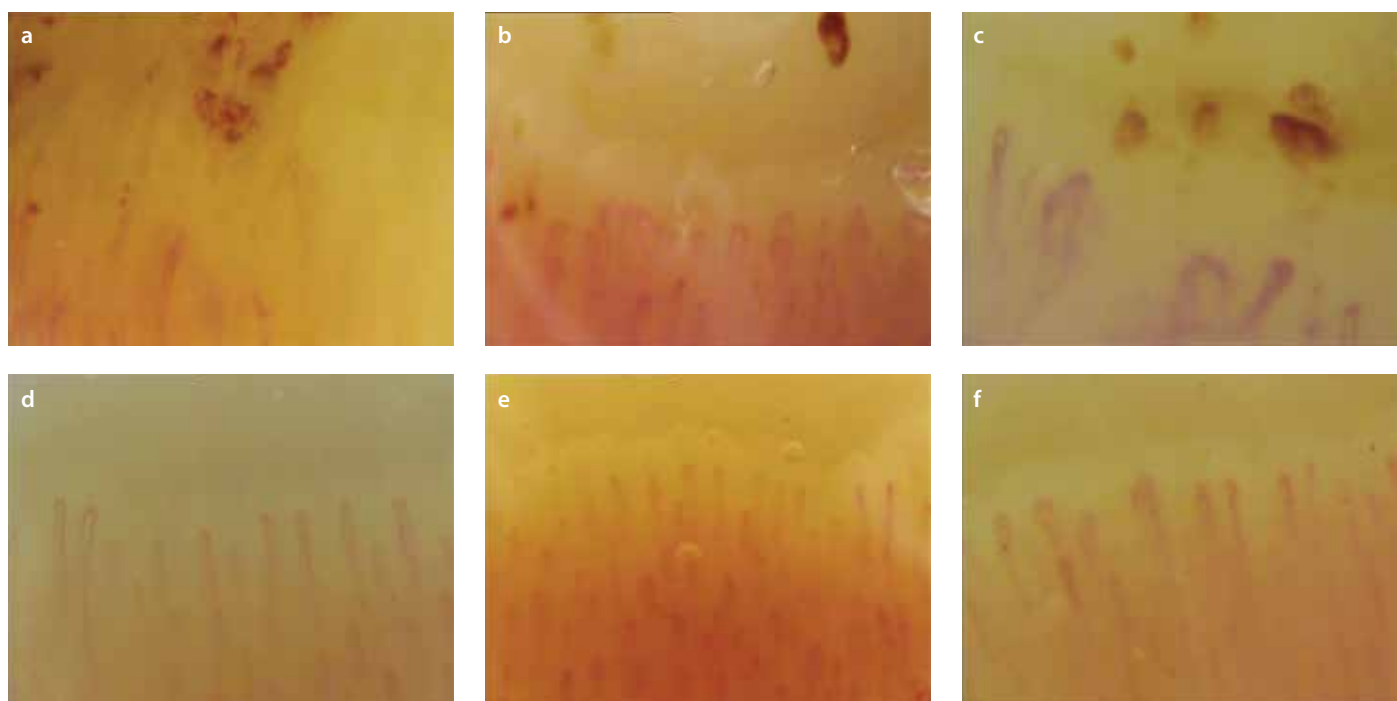
apart from rare and isolated enlarged loops and tortuosity; microhemorrhages and giant capillaries were no longer observable, and the foggy aspect disappeared (Figure 2).

## Discussion

Our observations provide evidence of a severe rearrangement of the nailfold vasculature, consistent with a segmental, inflammatory vasculitis occurring in TAO. Capillaroscopic abnormalities during the acute early phase were similar in both patients, suggesting that these abnormalities could be related to TAO.



**Figure 1. a, b.** Clinical aspect of the hand of one Buerger's patient during the acute phase (a) and after 6-month treatment (b)



**Figure 2. a-f.** Capillaroscopic images of one Buerger's patient during the acute phase (a-c) and after 6-month treatment (d-f)

Although such capillaroscopic findings share common features with a scleroderma-like pattern, including the presence of mega-capillaries and micro-hemorrhages, the absence of further clinical as well as serological data helped us to exclude a diagnosis of connective tissue disorders.

Capillaroscopic changes recorded after 6 months of evaluation, paralleled by the clinical improvement, led us to hypothesize a potential role of NFC during the follow-up period. Similarly, Sulli et al. (8) suggested that NFC should be performed at 6-month intervals in SSc patients with an early scleroderma pattern in order to identify possible rapid evolution of the microangiopathy to the active scleroderma pattern.

In conclusion, we suggest that TAO should be considered in the differential diagnosis of patients with acral ischemic ulcers and RP asso-

ciated with a capillaroscopic scleroderma-like pattern and that NFC could be an useful and non-invasive diagnostic tool for diagnosis and evaluation of disease progression and response to treatment.

**Ethics Committee Approval:** N/A

**Informed Consent:** N/A

**Peer-review:** Externally peer-reviewed.

**Author contributions:** Concept - G.M.G., M.B., A.F., E.S.; Design - G.M.G., M.B., A.F., E.S.; Supervision - G.M.G., M.B., A.F., E.S.; Resource - G.M.G., M.B., A.F., E.S.; Materials - G.M.G., M.B., A.F., E.S.; Data Collection&/or Processing - G.M.G., M.B., A.F., E.S.; Analysis&/or Interpretation - G.M.G., M.B., A.F., E.S.; Literature Search - G.M.G., M.B., A.F., E.S.; Writing - G.M.G., M.B., A.F., E.S.; Critical Reviews -G.M.G., M.B., A.F., E.S.

**Acknowledgements:** We would like to thank to Dr. Michele Bursi for editing images.

**Conflict of Interest:** No conflict of interest was declared by the authors.

**Financial Disclosure:** The authors declared that this study has received no financial support.

## References

1. Olin JW. Thromboangiitis obliterans (Buerger's disease). *N Engl J Med* 2000; 343: 864-9. [\[CrossRef\]](#)
2. Piazza G, Creager MA. Thromboangiitis obliterans. *Circulation* 2010; 121: 1858-61. [\[CrossRef\]](#)
3. Dargon PT, Landry GJ. Buerger's disease. *Ann Vasc Surg* 2012; 26: 871-80. [\[CrossRef\]](#)
4. Cutolo M, Pizzorni C, Secchi ME, Sulli A. Capillaroscopy. *Best Pract Res Clin Rheumatol* 2008; 22: 1093-108. [\[CrossRef\]](#)
5. Cortes S, Cutolo M. Capillaroscopic patterns in rheumatic diseases. *Acta Reumatol Port* 2007; 32: 29-36.
6. De Angelis R, Grassi W, Cutolo M. A growing need for capillaroscopy in rheumatology. *Arthritis Rheum* 2009; 61: 405-10. [\[CrossRef\]](#)
7. Maricq HR. Prevalence of a high nailfold plexus visualization score (PVS) in the general population. *Hum Biol* 1977; 49: 485-7.
8. Sulli A, Pizzorni C, Smith V, Zampogna G, Ravera F, Cutolo M. Timing of transition between capillaroscopic patterns in systemic sclerosis. *Arthritis Rheum* 2012; 64: 821-5. [\[CrossRef\]](#)