Indian Journal of Rheumatology 2011 December
Volume 6, Number 4; pp. 185–191

Review Article

Nailfold capillaroscopy: A cost effective practical technique using digital microscope

Vivek Vasdev[1], Darshan S Bhakuni[2], Aprajita Bhayana[3], Parul Kamboj[4]

ABSTRACT

Nailfold capillaroscopy (NFC) is a simple and non-invasive technique for the analysis of microvascular abnormalities seen in various systemic connective tissue diseases (SCTD), especially in systemic sclerosis (SSc) group of disorders. The techniques for NFC have evolved over several decades and nailfold video capillaroscope (NVC) is considered the gold standard tool for NFC. Nailfold video capillaroscope is an expensive equipment and usually not available in most developing countries. Other instruments that have been utilised for NFC are a magnifying lens, an ophthalmoscope, a dermatoscope, a stereomicroscope and a wide field microscope. Faced by shortcomings of multiple instruments, we have innovated a cost effective and simple technique for NFC using a handheld and universal serial bus (USB) digital microscope. This article elaborates on the advantages and disadvantages of various instruments and techniques for NFC, with emphasis on our innovative techniques. We recommend USB digital microscope for NFC in clinical practice especially for evaluation of scleroderma-related disorders.

Keywords: *Nail fold capillaroscopy, Raynaud's, digital microscope*

INTRODUCTION

Nailfold capillaroscopy (NFC) is a simple and non-invasive technique for the analysis of microvascular abnormalities seen in various systemic connective tissue diseases (SCTD), especially in systemic sclerosis (SSc) group of disorders.[1,2] It is an established fact that the presence of Raynaud's phenomenon (RP) should promptly lead to NFC, in order to distinguish between the primary and the secondary RP. Nailfold capillaroscopy has an exceptionally high negative predictive value and good positive predictive value for early distinction between primary and secondary RP. Besides SSc, NFC abnormalities have been documented in several other SCTD and systemic diseases with microangiopathic involvement, such as diabetes mellitus (DM) and coronary artery disease (CAD). The techniques for NFC have evolved over several decades with the advent of technology and experience. Presently, the gold standard tool for NFC is a nailfold video capillaroscope (NVC).[3,4] Nailfold video capillaroscope is an expensive equipment and usually not available in most developing countries. Despite the obvious advantages and the undisputed diagnostic value, NFC using NVC largely remains underutilised, mainly due to cost factors, lack of expertise and availability issues. Other instruments that have been utilised for NFC are a magnifying lens, an ophthalmoscope, a dermatoscope, a stereomicroscope and a wide field microscope. The aim of this article is to discuss the advantages and disadvantages of various instruments and techniques for NFC, with emphasis on our innovative techniques using a handheld microscope and a universal serial bus (USB) digital microscope.

HISTORICAL BACKGROUND

The first account of capillaroscopic abnormalities in SSc was given by Brown and O'Leary in 1925 that led to

[1]Associate Professor, Department of Rheumatology and Clinical Immunology, [4]Resident, Department of Dermatology, Command Hospital (Air Force), [3]Resident, Aerospace Medicine, Institute of Aerospace Medicine, Bengaluru, [2]Professor, Department of Rheumatology and Clinical Immunology, Army Hospital Research and Referral, New Delhi, India.
Correspondence: *Wg Cdr Vivek Vasdev, email: vasapra@gmail.com*
doi: 10.1016/S0973-3698(11)60205-7

association of SCTD with NFC changes.[5] Since then, many investigators have used NFC for studying several diseases in the early 20th century. However, this investigation largely remained underutilised for several decades, until Maricq et al. renewed the interest in NFC with his landmark article in Arthritis and Rheumatism, describing specific capillaroscopic patterns in SSc, as well as changes in microcirculation with RP using photographic panoramic technique.[6] While most of the earlier published data on NFC, relied on macrophotography and stereomicroscopy with or without imaging, almost all current research papers are based on NVC.

DESCRIPTION OF INSTRUMENTS USED FOR NAILFOLD CAPILLAROSCOPY

Following is the description of NFC with various instruments including our innovative techniques that have been

Table 1 Analysis of various instruments for nailfold capillaroscopy

Technique	*Advantages*	*Disadvantages*
Magnifying glass (with inbuilt light source)	Ease of use Easy availability Cost factor	Low magnification 5–10× Can visualise only gross capillary dilatation
Ophthalmoscope	Easy availability	Low magnification 10–20× Can visualise only gross NFC changes Difficult to use for operator Poor reproducibility No option for storing images
Dermatoscope	Easy availability in dermatology practise	Same as ophthalmoscope
Hand held microscope	Ease of use Easy availability Cost effective Small size Acceptable magnification 20–40× Acceptable resolution and sensitivity for major NFC changes	No option for storing images Cannot be used for subtle NFC changes or research activities
Stereomicroscope	Moderate cost Good resolution and magnification	Cumbersome Not available in most OPDs Specialised training required Additional camera and fibreoptic light source required Time consuming
Nailfold video capillaroscope	Ideal tool for research activities Magnification up to 600× Excellent image quality reproducibility	Prohibitive cost Availability Needs specialised training Time consuming Cannot be used bedside or in OPDs
USB digital microscope	Ease of use and availability Cost factor Small size Quick operation magnification up to 200× Good resolution Excellent sensitivity Ideal for bedside NFC and OPD care No special training required	Not an ideal tool for research purposes

NFC = nailfold capillaroscopy; OPD = outpatient department; USB = universal serial bus.

utilised for NFC over the years. The major advantages and disadvantages of each technique are summarised in Table 1 and the photographs of instruments are shown in Figure 1.

1. Magnifying glass—A simple handheld magnifying glass preferably with self-illumination can magnify up to 10× and visualise gross dilatation of capillaries especially in some SSc subjects with florid microvascular abnormalities. However, the resolution and discriminatory power of this technique is not good enough for any significant utilisation in clinical practice.
2. Ophthalmoscope—An easily available instrument in most centres with a usual magnification of 10× and 20× in some high end instruments. However, using this instrument for NFC is rather uncomfortable for the observer and it takes some experience before the observer can effectively utilise this technique. Moreover, the low magnification, poor reproducibility and inability to store images, makes it a poor instrument for NFC. It is not cost effective since the price range varies between INR 5000 and INR 20,000. We have not found this instrument to be good enough for meaningful NFC in clinical or research environment.
3. Dermatoscope—A widely used self-illuminating instrument in dermatology practice can be used for NFC. However, it has the same set of disadvantages as an ophthalmoscope in terms of low magnification, poor reproducibility and inability to store images for future reference. In addition, it is usually not available in rheumatology practice. It can still be utilised effectively where it is readily available, especially in dermatology practice. Our experience with this instrument is limited, but knowing the magnification characteristics, optics, and other obvious shortcomings, it seems to be comparable to an ophthalmoscope for NFC.
4. Hand held microscope—A simple, readily available, pocket sized, inexpensive instrument with a resolution of 20–50×. Its use in NFC has not been documented in literature so far, but, we have been using this instrument for bedside NFC for >3 years with acceptable results. The major advantage is its small size, low cost, acceptable magnification, and good discriminatory capacity. Moreover, there is no requirement of formal training or additional gadgets such as a desktop computer/laptop. The disadvantage is in inability to store images for future reference. It is easily available on most marketing websites such as www.ebay.in; however, the claimed magnification in most advertisements is not achievable. It is cost effective with price ranging from INR 400 to INR 900. We feel that despite its inability to store images, it is a cost effective, portable, easy to use instrument for NFC during ward rounds or outpatient department (OPD) practice where computers are not available.
5. Stereomicroscope—This is the most commonly used instrument for NFC in published studies with a resolution range from 10 to 200×. Images can be stored using conventional camera or a digital camera. Video recording can also be done by attaching a digital video camera. The stored image quality is good and depends on the resolution of camera and optics. Its major disadvantages are size, poor availability, training and inadequacy for use in clinical setting. The cost of a good stereomicroscope ranges from INR 80,000 to INR 200,000 and additional expenses for imaging facility.
6. Videocapillaroscopy—NVC is currently the gold standard for NFC and utilised for most studies on NFC that are published in recent times. The image quality is excellent and videocapillaroscopy can be performed with this device. However, this is an expensive instrument (INR 24,00,000–45,00,000), requires specialised training and usually not available in developing countries. Owing to these constraints, none of the Indian centres is equipped with this instrument. Another major disadvantage is that it cannot be used as an OPD/bedside investigation owing to the size of the equipment. This is an ideal instrument for research purposes owing to excellent imagery and software for objective analysis of various microvascular characteristics.
7. Universal serial bus digital microscope—We are the pioneers in utilisation of this instrument for NFC. It is a widely available, inexpensive instrument that can be attached to a computer via USB port. We hit upon the idea of its application in NFC after noticing a hardware engineer using it to magnify small circuit and recording images on a computer. We experimented with this simple device for NFC and got excellent results comparable to other expensive and cumbersome instruments that are presently considered as gold standards. The images or video can be seen on a computer monitor and saved for future reference. The instrument is capable of recording images up to 200×. The quality of stored images can also be enhanced or edited utilising any picture manager software. It can also record videos of NFC and be utilised as a video capillaroscope. This technique does not require any special software, expertise or training and can be mastered in a few sessions. This instrument is readily available on most internet marketing websites for INR 3000–8000. We have 3 years of experience with this instrument and examined >1000 patients of SCTD or other systemic disorders with microangiopathy. We have devised our own innovative techniques to overcome certain shortcomings such as inability to calculate capillary density, which will be described later.

NAILFOLD CAPILLAROSCOPY TECHNIQUE UTILISING UNIVERSAL SERIAL BUS DIGITAL MICROSCOPE

We were fascinated by the diagnostic capabilities and myriad uses of NFC in rheumatologic and non-rheumatologic conditions with microvascular abnormalities. However, non-availability of NVC was a major hurdle that made us explore other modalities. Faced by various shortcomings with other conventional modalities for NFC and after months of experimenting, we have devised an innovative technique utilising a commonly available inexpensive USB digital microscope (Figure 2). This technique is mainly suitable for carrying out NFC quickly in an OPD or bedside examination. However, it can still be effectively utilised for recording most parameters required in research protocols with certain modifications as described below.

Procedure

The subject is seated and hands placed on examination table. The nailfold is gently cleaned and smeared with transparent jelly or liquid paraffin to improve visualisation of capillaries. The standard literature mentions the use of cedar wood oil for this purpose; however, it is not readily available in the Indian market. The major drawback with use of oil or liquid paraffin is that it runs down from the nail bed and needs to be replaced during prolonged NFC. Also, one needs to be careful to prevent soiling of the examining table and the clothes used during the procedure. Due to these problems, we experimented with transparent jelly, since it is devoid of problems faced with the liquids as mentioned above. In our clinic, we use readily available ultrasonography jelly or lignocaine jelly.

We prefer examining all fingers except thumbs for complete NFC. However, for screening purposes in a busy OPD, we examine only ring and little finger of the non-dominant hand. With our experience, these two fingers yield best results and good enough for preliminary examination. We carry out NFC with a digital microscope at 30× and 100× magnification. The images are stored in a computer for analysis at a later date. On an average, the screening of two fingers including recording images takes < 5 minutes. A complete NFC recording of all fingers might take 15–20 minutes. We store the images and videos on the computer for analysis and record keeping. We analyse the stored images for linear capillary density, capillary tortuosity, variability in capillary length, number of enlarged capillaries, avascular areas and presence of disorganised architecture. The stored images can be further enhanced for optimal study by changing contrast and brightness with readily available easy to use software such as Microsoft picture manager. We classify the observed changes in NFC as normal, scleroderma pattern or non-specific abnormalities. 'scleroderma pattern' is characterised by the presence of dilated capillaries, megacapillaries and decreased capillary density with vascular deletion areas. Non-specific capillary loop abnormalities include mild capillary dilatation, variability of loop length and mildly reduced capillary density. Further elaboration and discussion on NFC abnormalities is beyond the scope of this article. Some of the images and typical abnormalities recorded with this gadget are shown in Figure 3.

We faced a problem while calculating linear capillary density in real time and on stored images with this device. We overcame this problem by recording images along with a millimetre scale placed perpendicular to length of capillaries. After experimenting with various scales, we find using a paper strip with millimetre markings (ideal is the readily available Schirmer's test strip) for more convenience. This paper strip is wrapped around the finger near nail bed and can be photographed along with capillaries for calculation of capillary density (Figure 3).

Future directions

We are in the process of developing software that can be incorporated with USB digital microscope to further enhance the image quality and analyse multiple characteristics of NFC required for research activities.

DISCUSSION

The consensus emphasises that all patient with RP should undergo a NFC examination to assist in characterising the clinical and evolving profile.[7,8] Besides, there is a myriad of information that can be obtained by NFC in various SCTD and other systemic diseases with microangiopathy. One of the best advantages for clinicians can have with NFC is its high negative predictive value for connective tissue disease (CTD) (>90%) in subjects with RP.[9,10] On the other hand, its positive predictive value is only about 50%, but this is higher than any other single screening test.[9] This investigation largely remains underutilised, since the gold standard for this investigation is inaccessible to most clinicians. The other documented methods for NFC fall short of expectations of clinicians, in respect of sensitivity, resolution, reproducibility and practicality in clinical settings. The major drawbacks for use of NVC for NFC are its prohibitive cost, time



Figure 1 Instruments for nailfold capillaroscopy. (A) Macrophotography with high magnification lenses. (B) Dermatoscope. (C) Handheld microscope. (D) Stereomicroscope. (E) Videocapillaroscope. (F) Universal serial bus digital microscope.



Figure 2 A universal serial bus digital microscope for nailfold capillaroscopy.

factor, need for special training and its non-suitability for use in the OPD services. The other described instruments are either too cumbersome for use in clinical settings or provide insufficient information. We feel that an ideal tool for NFC in clinical setting should be simple, portable, quick to operate, provide instant results and should not require any special training or expertise. It should be able to record basic NFC parameters, distinguish major abnormalities, store images for further reference and most of all differentiate between primary and secondary RP. Last but not the least it should be readily available and cost effective. All these above-mentioned requirements can be fulfilled by the USB digital microscope. We have the experience of using this instrument for NFC for >3 years and carried out >2000 NFC for various SCTD and other systemic diseases. The quality and resolution of the images captured with this device may not exactly match NVC, nevertheless, they are good enough for use in clinical setting.

CONCLUSION

Our innovative techniques of using handheld microscope and USB digital microscope for NFC are ideal for clinicians,

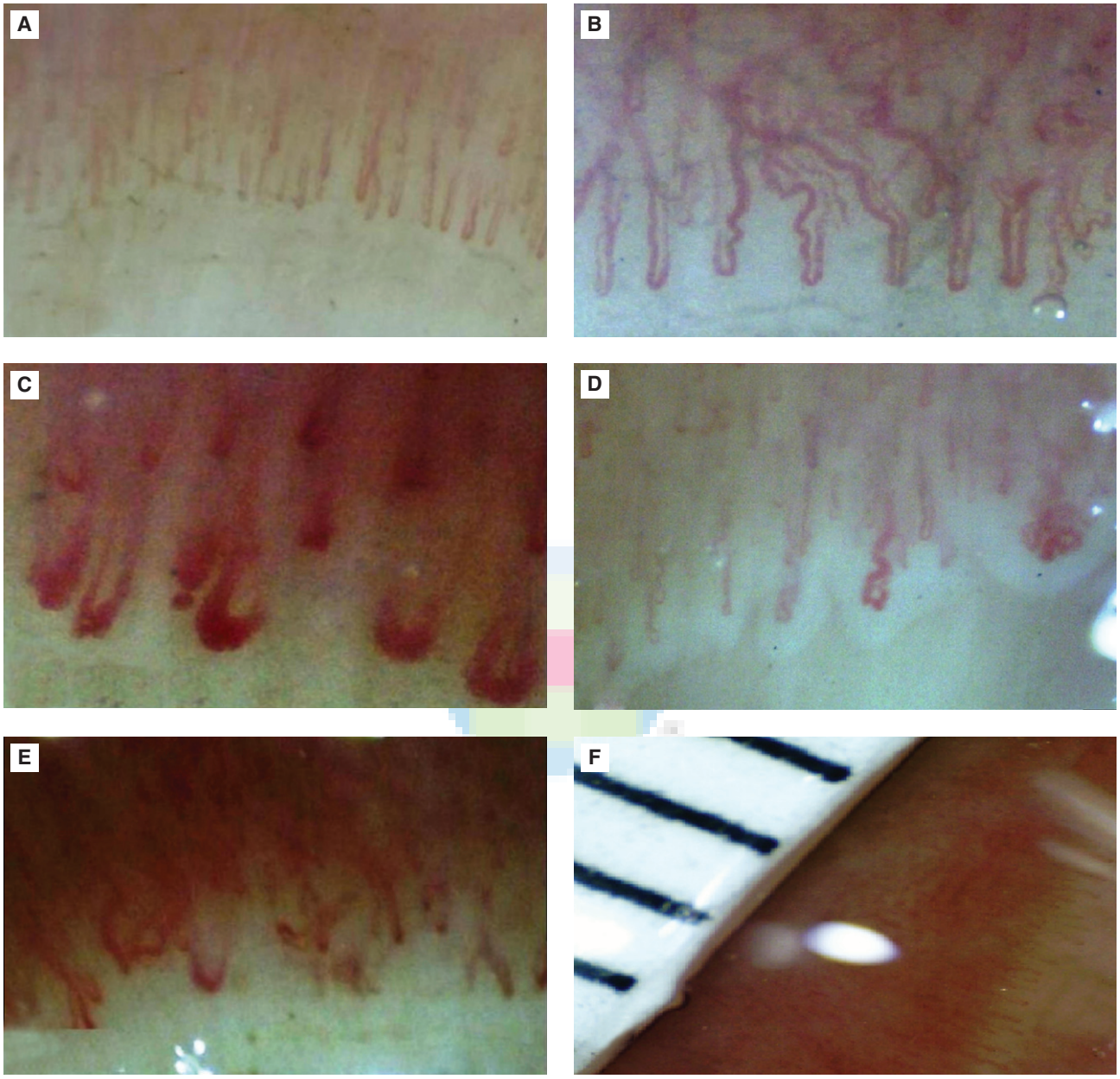

Figure 3 Characteristic nailfold capillaroscopy (NFC) findings in subjects using universal serial bus digital microscope. (A) Normal NFC at 30×. (B) Normal NFC at 100×. (C) Dilated capillary loops with reduced capillary density in systemic sclerosis. (D) Non-specific dilatation and tortuosity in systemic lupus erythematosus. (E) Completely disorganised architecture in advanced systemic sclerosis. (F) Measurement of capillary density by photographing millimetre scale along with capillaries.

especially in busy clinical scenarios. The handheld microscope is suitable for bedside NFC and OPD NFC where computer facilities are not available. The USB digital microscope has the major advantages in excellent image and video quality with storage facility, ease of use, reproducibility, no formal training, cost and time factor. All this comes at a fraction of a price of NVC and ideal for resource poor countries. The only disadvantage is that it is less than ideal technique for

modern research activities. However, we hope to resolve that soon with the advent of new software. Currently, we recommend it as a simple, inexpensive and, easy to use technique for office NFC.

REFERENCES

1. Cutolo M, Pizzorni C, Sulli A. Capillaroscopy. Best Pract Res Clin Rheumatol 2005; 19: 437–52.
2. Cutolo M, Grassi W, Matucci Cerinic M. Raynaud's phenomenon and the role of capillaroscopy. Arthritis Rheum 2003; 48: 3023–30.
3. De Angelis R, Cutolo M, Salaffi F, Pablo Restrepo J, Grassi W. Quantitative and qualitative assessment of one rheumatology trainee's experience with a self-teaching programme in video-capillaroscopy. Clin Exp Rheumatol 2009; 27: 651–3.
4. De Angelis R, Grassi W, Cutolo M. A growing need for capillaroscopy in rheumatology. Arthritis Rheum 2009; 61: 405–10.
5. Brown GE, O'Leary PA. Skin capillaries in scleroderma. Arch Intern Med 1925; 36: 73–88.
6. Maricq HR, LeRoy EC. Patterns of finger capillary abnormalities in connective tissue disease by 'wide-field' microscopy. Arthritis Rheum 1973; 16: 619–28.
7. Ingegnoli F, Boracchi P, Gualtierotti R, Lubatti C, Meani L, Zahalkova L, et al. Prognostic model based on nailfold capillaroscopy for identifying Raynaud's phenomenon patients at high risk for the development of a scleroderma spectrum disorder: PRINCE (Prognostic Index for Nailfold Capillaroscopic Examination). Arthritis Rheum 2008; 58: 2174–82.
8. Block JA, Sequeira W. Raynaud's phenomenon. Lancet 2001; 357: 2042–8.
9. Spencer-Green G. Outcomes in primary Raynaud phenomenon. A meta-analysis of the frequency, rates, and predictors of transition to secondary diseases. Arch Intern Med 1998; 158: 595–600.
10. Cutolo M, Sulli A, Secchi M, Olivieri M, Pizzorni C. The contribution of capillaroscopy to the differential diagnosis of connective autoimmune diseases. Best Pract Res Clin Rheumatol 2007; 21: 1093–108.